

Review article

Management and endoscopic techniques for digestive foreign body and food bolus impaction[☆]

Armelle Chauvin^a, Jerome Viala^b, Philippe Marteau^a, Philippe Hermann^c, Xavier Dray^{a,*}

^a Emergency Endoscopy Unit, Department of Gastroenterology, APHP, Lariboisière Hospital, & iTEC Paris Diderot Paris 7 University, Paris, France

^b Department of Pediatric Gastroenterology, APHP, Robert Debré Hospital, & Denis Diderot, Paris 7 University, Paris, France

^c Department of Otorhinolaryngology, APHP, Lariboisière Hospital, & Denis Diderot, Paris 7 University, Paris, France

ARTICLE INFO

Article history:

Received 3 October 2012

Accepted 2 November 2012

Available online 23 December 2012

Keywords:

Eosinophilic esophagitis

Foreign body

Food bolus impaction

Endoscopy

Therapeutic endoscopy

Esophageal perforation

Stent

Capsule retention

Battery

Coin

ABSTRACT

Ingested foreign bodies, food bolus impaction, migration or retention of medical devices are frequent, in children as well as in adults. Most of these foreign bodies will naturally pass through the gastrointestinal tract. Complications are rare but sometimes severe (oesophageal perforations are the most frequent and most feared). We aimed to review the literature on therapeutic management of digestive foreign bodies and food bolus impaction, with special focus on endoscopic indications, material, timing and techniques for removal. The role of the gastroenterologist is to recognise specific situations and to plan endoscopic removal in a timely manner with the most adequate conditions and extraction tools. Risk factors and underlying pathology, for example eosinophilic esophagitis, must be investigated and if necessary treated.

© 2012 Editrice Gastroenterologica Italiana S.r.l. Published by Elsevier Ltd. All rights reserved.

1. Introduction

Foreign body ingestion (127,000 a year in the USA) and food bolus impaction frequently occur [1] and represent about 4% of all emergency endoscopies [2]. Clinical situations are varied and require a skilled operator with adapted extraction tools. We reviewed the literature on therapeutic management of digestive foreign body and food bolus impaction, with special focus on endoscopic indications, material, timing and techniques for removal. The specific cases of sword swallowers [3] and rectal foreign bodies [4] will not be detailed herein.

2. Epidemiology

2.1. Children

Seventy-five percent of foreign bodies are ingested by children younger than 5 years old [1]. Coins, buttons, plastic pieces, batteries

and bones are far more frequent than the expected toys [5,6]. Ten percent of children experience a recurrent ingestion [7]. Underlying oesophageal diseases are likely to be seen in children with foreign body impaction (more than 80% in some series, including 53% of patients with eosinophilic oesophagitis) [8]. Only 10–20% require endoscopic removal, while less than 1% will need surgery for foreign body extraction or to treat a complication [9].

2.2. Adults

Foreign body ingestion is accidental in more than 95% of adult cases, and food-related (food impaction, animal bones, toothpicks) in two thirds of cases (steakhouse syndrome, Figs. 1–3) [2]. Fish bones are the most frequent in Asia [10,11]. Coins are the most frequent non-alimentary foreign body ingested by adults [12]. Accidental ingestion also sometimes occurs during dental procedures. Voluntary foreign body ingestion are sometimes seen in psychiatric patients (Figs. 4–6) [13], in prisoners (seeking some secondary gain with access to a medical facility) and in drug dealers (also known as “drug-mules” or “bodypackers”). Underlying diseases facilitating foreign body impactions are frequent (more than 30% [2], including dentures, pre-existing oesophageal disorders (eosinophilic esophagitis in 10% [14], oesophageal motor disturbances, stenosis and diverticulae) (Figs. 1 and 2).

[☆] No support in the form of grants, equipment, drugs, or all of the above.

* Corresponding author at: Department of Gastroenterology, Lariboisière Hospital APHP & Paris 7 University, 2, rue Ambroise Paré 75010 Paris, France. Tel.: +33 1 49 95 25 45; fax: +33 1 49 95 25 77.

E-mail address: xavier.dray@lrh.aphp.fr (X. Dray).

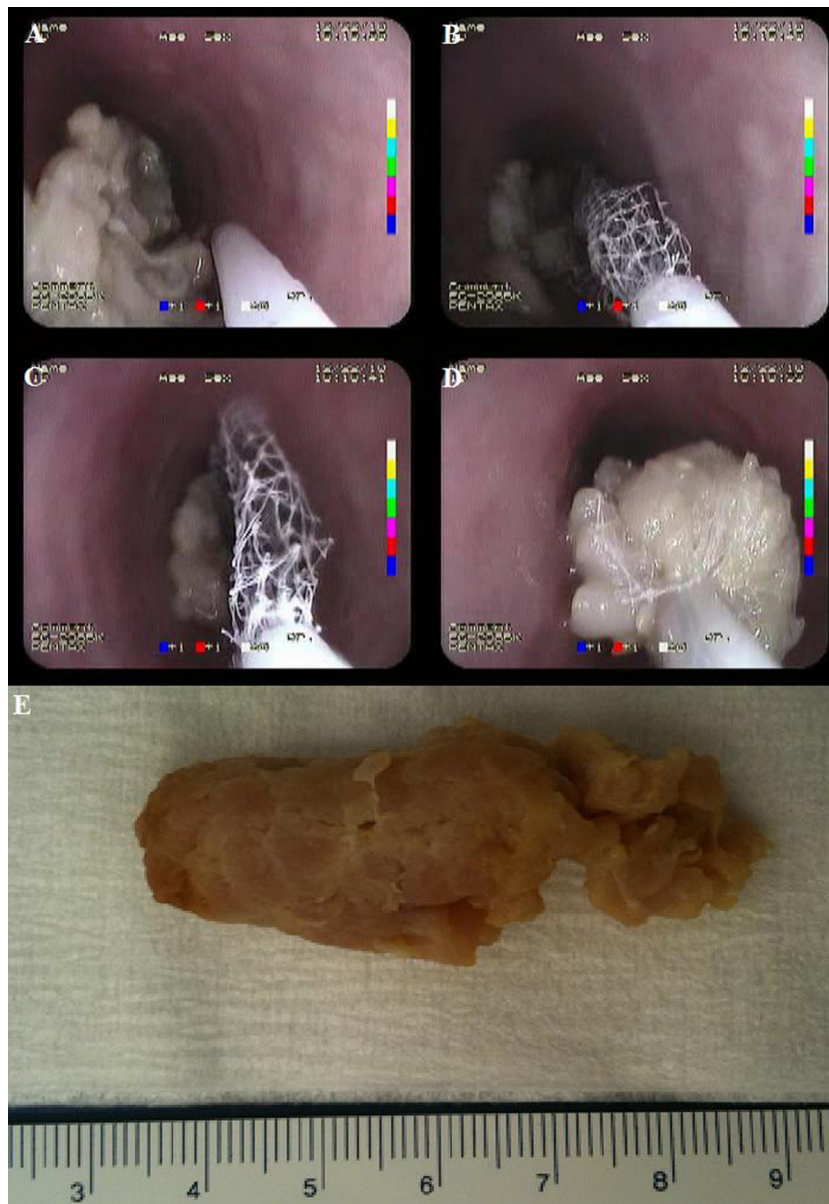


Fig. 1. 25 year-old male patient with first episode of food bolus impaction (meat). (A) Food bolus is located at the second third of the oesophagus. (B,C) A polyp retrieval net is inserted along the food bolus, (D) allowing the en-bloc removal of the 6 cm-long meat bolus. Discharged, uneventful outcome. Diagnostic of eosinophilic esophagitis was upheld on elective endoscopy.

2.2.1. Digestive segments at risk of complication, with relation to indication and timing

Although 80% of foreign bodies can pass through naturally (in adults as well as in children [15]), some will remain blocked in the narrower segments of the digestive tract.

The oesophagus is the most frequent site of blockage (50–75%) [2,10]. Foreign bodies impacted in the oesophagus are particularly at risk of complication because of its thin wall and because of numerous physiological (cricopharyngeal sphincter, aortic arch and diaphragmatic hiatus) and putative non-physiological narrowings (oesophagus atresia or stenosis, cardiac achalasia, cancer, post-surgical or congenital modification of anatomy [16,17]). The risk of complication is 25% higher in the upper oesophagus than in other sites [18]. Working space is limited, particularly in the cervical oesophagus (Fig. 3). Moreover, the vicinity of vital organs around the oesophagus makes many complications life-threatening [19,20]. These anatomic and high-risk features lead to remove any object without delay particularly in the following

conditions: (i) involvement of the upper third oesophagus; (ii) symptoms of complete obstruction; (iii) at-risk objects (such as sharp foreign bodies or batteries) [21]. In such emergency cases, the endoscopic removal should not be delayed whether the stomach is empty or full. Any other foreign body lodged in the oesophagus should be managed within the 24 h following the ingestion [21], because the risk of complication increases by 2 and by 7 fold with oesophageal retention lasting 24 and 72 h, respectively [18].

Foreign bodies that have reached the stomach have a chance to be evacuated spontaneously, while the thickness of the gastric wall limits the risk of perforation. Therefore, endoscopic removal is recommended only for dangerous foreign body to avoid them passing the duodenal curve [21]. Blunt and small objects should be extracted only if they are still present after 3–4 weeks [21].

When a sharp foreign body has passed the pylorus, perforation may occur especially in duodenum [22,23], or at the ileocaecal valve [24] or sometimes in a Meckel diverticulum [25–27]. A blunt object remaining in the duodenum should be removed within 8 days to

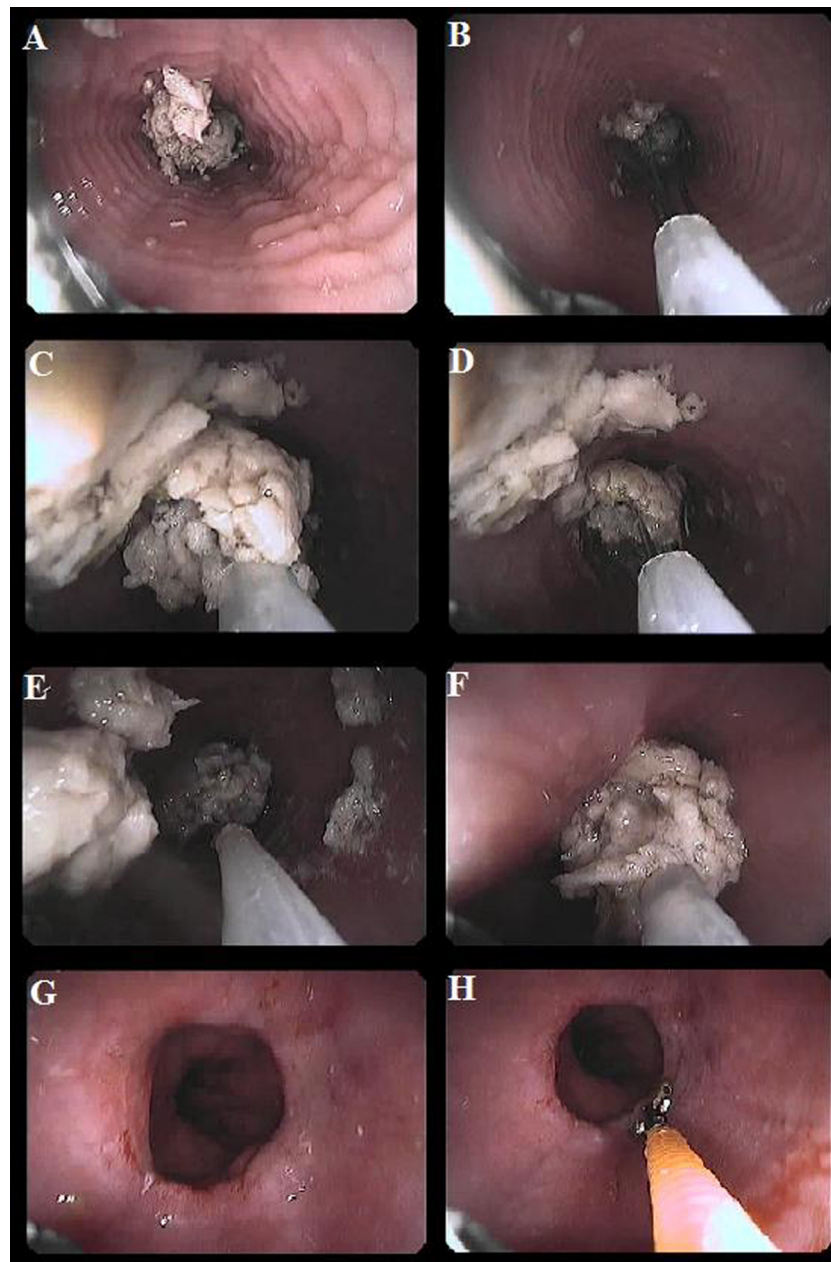


Fig. 2. 32 year-old male patient with first episode of food bolus impaction (meat). (A) Food bolus is located at the lower third of the oesophagus; a ringed trachea-like appearance of eosinophilic esophagitis is noticed; (B–E) a 4-prong grasper is used to breakdown and to extract the food bolus; (D) after complete removal of the food bolus, a stricture is clearly visible; (E) biopsies are performed. A diagnostic of eosinophilic esophagitis was confirmed.

limit the risk of ischaemia [21]. Sharp objects that passed the duodenal curve should be followed with daily radiographs, and surgical removal should be considered if the foreign body does not progress in 3 days [28].

3. Management

3.1. Initial evaluation

3.1.1. Clinical evaluation

The majority of patients remain asymptomatic following foreign body ingestion (up to 50% in paediatric series) [29]. This diagnosis should be suspected if symptoms such as dysphagia, vomiting, blood-stained saliva, hypersialorrhea, wheezing and/or respiratory distress are present in a patient unable to report the ingestion

(nonverbal children, patients with psychiatric disorders or mental retardation) [21]. Patients may localise discomfort with poor correlation to the site of impaction [1,21]. Signs of esophageal obstruction with inability to manage secretion need an urgent endoscopic retrieval [21]. Esophageal perforation may cause cervical crepitus, neck swelling or pneumomediastinum. Generally, when a foreign body has passed the oesophagus, it does not cause symptoms unless a complication occurs (obstruction or perforation).

3.1.2. Radiological evaluation

For patients with non-bony food impaction without complications, an endoscopy may be performed without any radiological work-out [21]. In other cases, X-ray examinations are used to assess the presence and number of radiopaque foreign body, their locations, sizes and shapes (Fig. 6) and to determine if obstruction

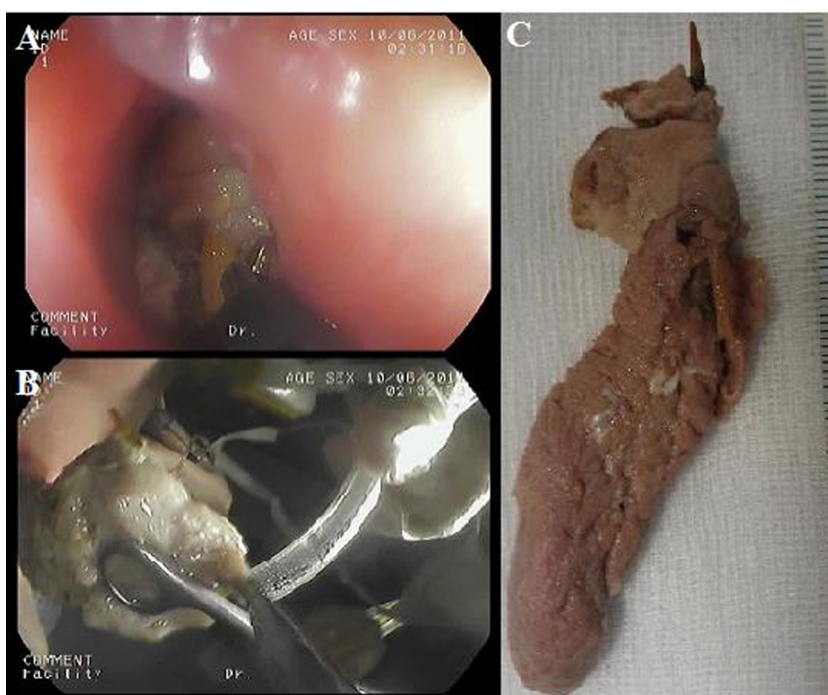


Fig. 3. 53 year-old male patient with food bolus impaction (meat) and sharp foreign body (toothpick). (A) Food bolus is located just below the upper oesophageal sphincter; the pointed end of the toothpick is grabbed with a reusable alligator-tooth foreign body grasper; (B) extraction is secured with a Macgill forceps in the hand of an otolaryngologist; (C) view of the food bolus with toothpick after removal. No mucosal damage or underlying esophageal disease was found during endoscopic inspection, immediately after removal. 24 h admission, uneventful outcome.

or perforation is present (Fig. 7). Biplane neck, chest or abdominal radiographs, as appropriate, are often sufficient, and CT scans are rarely needed [21,30]. Interestingly, coins or batteries display the same circular appearance: a lateral view of the foreign body helps to differentiate a coin from a battery, because of a 2-step border in the latter. However, ingestions of radiolucent foreign bodies are not rare (22 and 36% in adult and paediatric large cohorts, respectively [11,29]), and are related to bony and non-bony food bolus impactions in most cases [11]. Contrast studies should not be performed as they delay urgent endoscopies, or interfere with endoscopic visualisation [2]. Barium is contra-indicated when perforation is suspected, whereas hypertonic contrast agents can cause acute pulmonary oedema if aspirated [2]. Thus, when needed, CT scan exploration should be preferred to X-ray contrast study for evaluation of non-radiopaque objects [21,30].

3.2. Initial procedural management

3.2.1. Information and consent

When foreign body extraction is considered, then the procedure and the risks involved with the location, nature and shape of the foreign body have to be explained to the patient. This can be a challenging situation in psychiatric patients or in prisoners. Informed consent must be obtained. In a series of 414 cases in a tertiary care centre, signed consent was refused in only three cases [2].

3.2.2. Sedation

In most cases, upper gastro-intestinal endoscopy can be managed with conscious sedation (87% of cases in a series of 414 adult patients) [2]. The patient must be lying on their left side, with the head slightly lowered, to reduced inhalation risks. However, in difficult cases (younger children, poor patient tolerance, multiple objects, anticipation of difficult extraction, or when rigid oesophagoscopy is needed), general anaesthesia with endotracheal intubation for airway protection is more appropriate, usually

performed with a rapid sequence induction technique because of a full stomach.

3.3. Endoscopic and ancillary equipment

3.3.1. Endoscopes

In a child of less than 1 year-old, a nasogastroscope with an external diameter inferior to 6 mm should be used although it restricts the choice of operating devices. A 2 mm channel accepts only small polypectomy retrieval nets (diameter of 20 mm), polypectomy snares, or Dormia baskets.

In adults, standard flexible endoscopes (9.8 mm diameter scope, 2.8 mm diameter single channel) or therapeutic endoscopes (>3.2 mm diameter single channel) are used in most cases. Double-channel endoscopes permit a combination of devices (Fig. 6). Small-calibre endoscopes, via a transnasal approach, are sometimes needed [21]. Enteroscopes can be used when a sharp foreign body has passed the Treitz angle or for prolonged retention of bulky objects (capsules for instance) [31].

Rigid hypopharyngoscope with compatible forceps can be used for foreign body extraction in a hypopharyngeal or upper oesophageal sphincter location (Fig. 8). The main benefit is a large working channel with stronger grasping possibilities [32]. If the foreign body has stopped further, rigid oesophagoscopy can avoid repeated oesophageal intubations when fragmentation of a food bolus would otherwise be difficult with a flexible endoscope. However, complication rates are higher with rigid oesophagoscopy (10%) than with flexible endoscopy (5%) [33]. It is therefore recommended that otolaryngologists attempt rigid esophagoscopy for foreign body retrieval only when flexible endoscopy has failed.

3.4. Retrieval devices [34]

The most frequently used retrieval devices are rat-rooth and alligator forceps, tripang graspers, Dormia baskets, retrieval nets

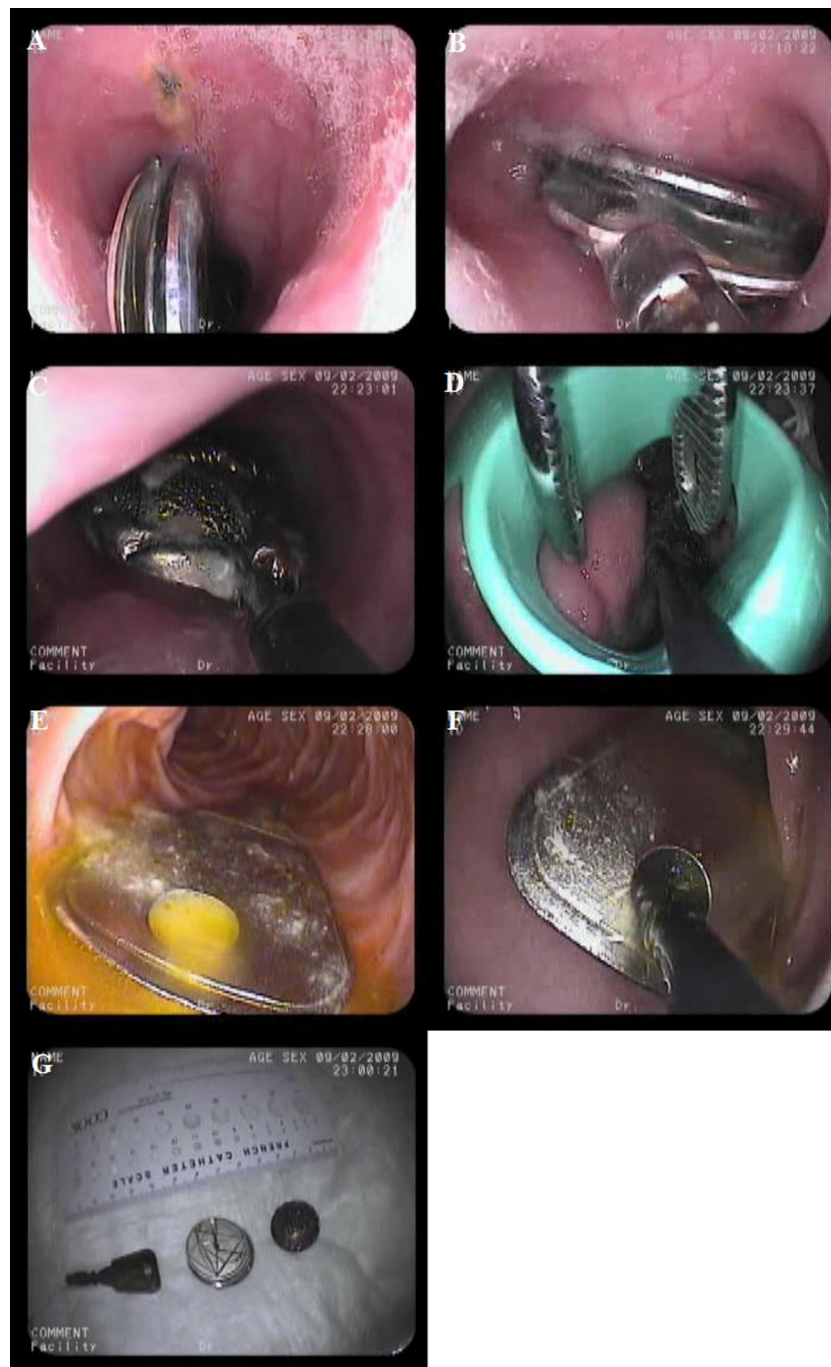


Fig. 4. 23 year-old female psychotic patient with numerous episodes of voluntary ingestion of foreign bodies, including a past history of gastrotomy. (A) Endoscopic extraction of a watch using a reusable alligator-tooth foreign body grasper; (B,C) the same foreign body grasper was used for extraction of a large button impacted downstream in the oesophagus, (D) with assistance of a MacGill forceps to pass the upper sphincter of the oesophagus. (E, F) A key in the second part of the duodenum was removed by inserting and opening the forceps through a hole in the key bow; (G) all foreign bodies were successfully removed with the same instrument.

and polypectomy snares (Table 1) [34]. The choice of the retrieval device is determined by the size and shape of the foreign body, by the endoscope length and instrument channel and by the endoscopist's preference and habits. Magnetic retrievers are no longer used because foreign bodies are often lost during retrieval [34].

3.4.1. Retrieval forceps

Standard biopsy forceps are often inadequate because of their small opening width, but they can be efficient for small and soft objects (Fig. 9). There is a large variety of other jaw configurations:

rat-tooth, alligator-tooth or shark-tooth forceps. The rat-tooth forceps is the most commonly used. A rubber-tip forceps can be useful for small hard objects, such as pins, needles or blades. Most of these devices are reusable, making their use inexpensive.

3.4.2. Retrieval graspers

Graspers can have 2–5 prongs. They can be useful to retrieve soft objects, such as food bolus impaction (Fig. 2), but must not be used for harder or heavy objects because the grip is not secure enough.

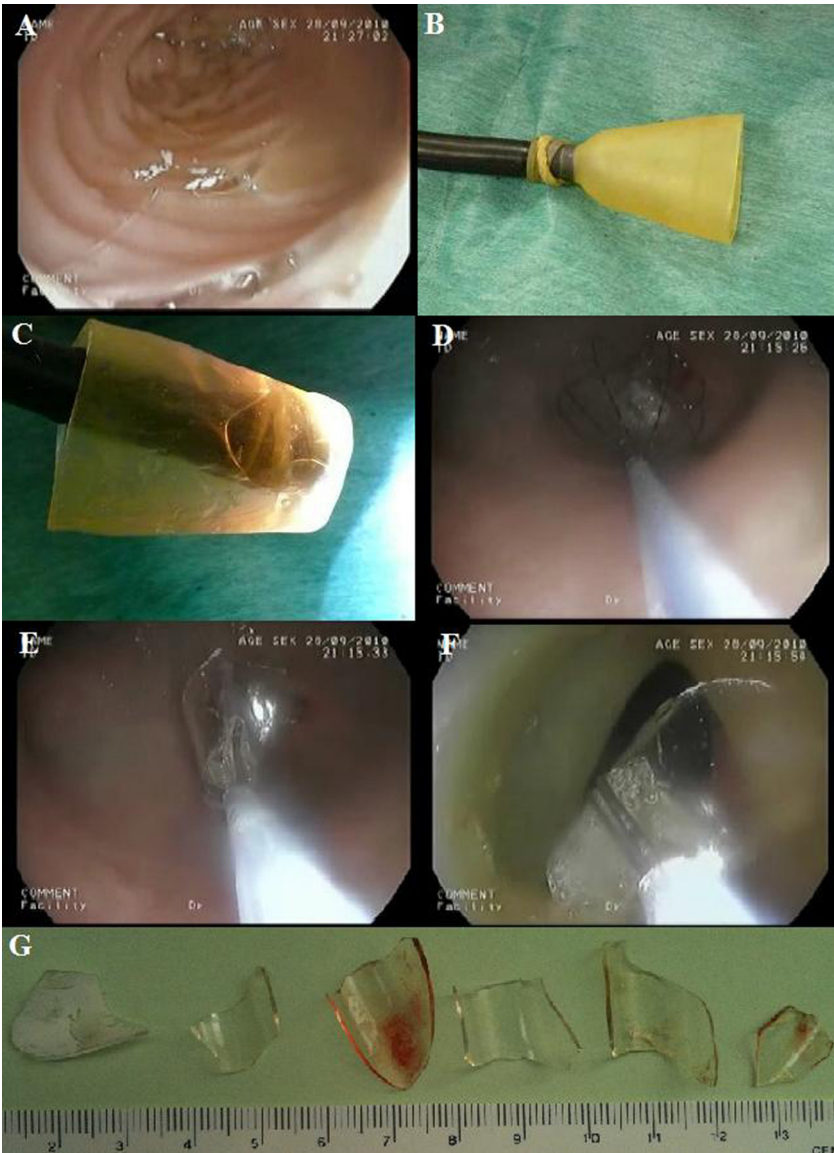


Fig. 5. same patient as in Fig. 4, seen a few months later, and referred for voluntary ingestion of glass fragments. Glass fragments were seen in the oesophagus, in the stomach and (A) in the duodenum; (B) a latex hood is attached to the tip of a standard gastroscope, (C) and flipped over the scope; (D,E) a glass fragment is grabbed with a rotative hemispheric basket, (F) and safely removed along the oesophagus, as the latex hood has unfurled over the basket while passing the cardia, thus protecting the digestive wall during withdrawal; (G) a total of six glass fragments were found and removed from the upper digestive tract in the same session. 48 h admission, uneventful outcome.

Table 1
Main characteristics of most widely used retrieval devices for endoscopic extraction of ingested foreign bodies and food bolus impaction.

Retrieval devices	Configuration	Size	Length	Specific aspects	Usual cost ^a
Snares	-Oval -Hexagonal -Crescent -Barbed -Jumbo snare	1 cm × 1.5 cm to 3 cm × 6 cm	105–240 cm	Single use or reusable devices available	+ to +++
Retrieval graspers	2-prong to 5-prong	1.3–2.5 cm	129–240 cm	Single use or reusable devices available	+ to +++
Baskets	3- to 6-wire baskets	0.5 cm × 1.3 cm to 2 cm × 4.3 cm × 6 cm	120–240 cm	Single use or reusable devices available	+ to +++
Retrieval nets	-Oval -Octagonal -Hexagonal	2 cm × 4.5 cm to 4 cm × 8 cm	160–230 cm	Single use	++
Retrieval forceps	Different jaw-designs: -Rat-tooth -Alligator-tooth -Shark-tooth -Rubber tip	Breadth of opening: 3–19.5 mm	120–230 cm	Most specialised forceps are reusable	+++

^a +, less than 50 euros; ++, 50–100 euros; +++, 100 euros and more.

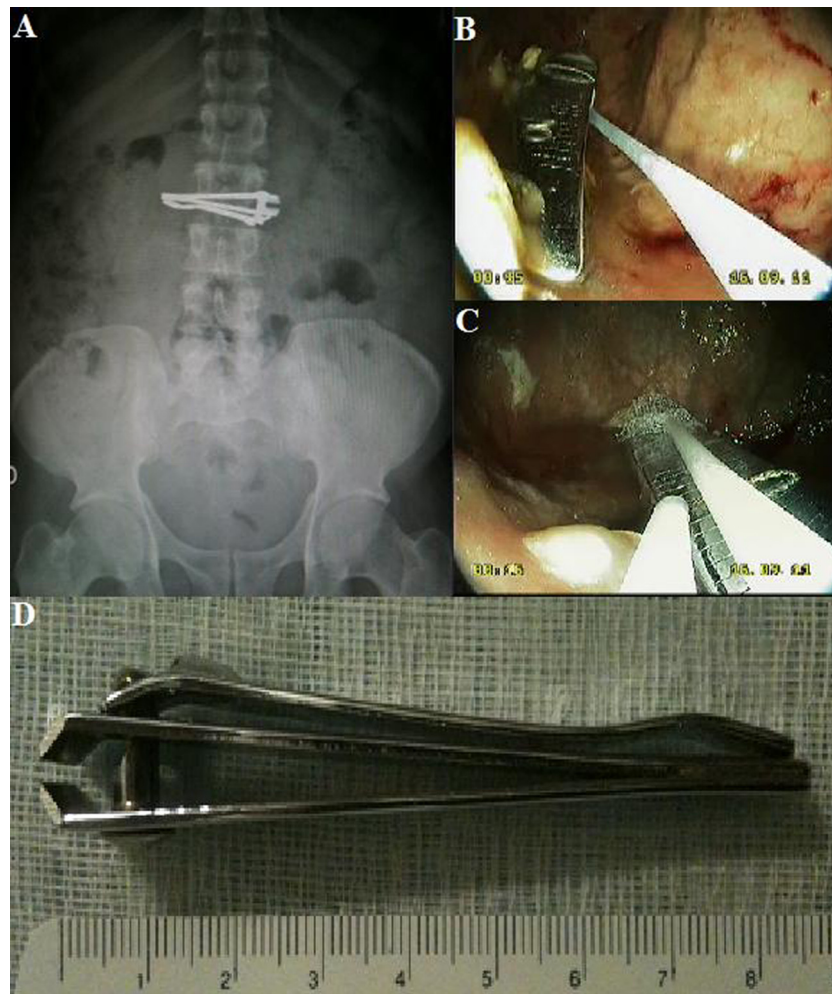


Fig. 6. 23 year-old male psychotic patient admitted for voluntary ingestion of a pair of nail clippers. (A) Emergency X-ray; (B) the nail clippers are grabbed with a polypectomy snare using a double channel endoscope; (C) the opposite end of the nail clippers is snared with a polyp retrieval net, in order to adjust the axis of the foreign body along the axis of the oesophagus; (D) view of the 8 cm-long nail clippers after removal. 24 h admission, uneventful outcome.

3.4.3. Baskets

Endoscopic baskets, such as Dormia basket, may be useful, especially for round objects that cannot be grasped with other devices (Fig. 5). Three, four and six-wire baskets are available. Retrieval baskets used with a duodenoscope during endoscopic retrograde cholangiopancreatography are too short to be used with a colonoscope, however colonoscopic retrieval baskets do exist.

3.4.4. Retrieval nets

Differences between the large variety of nets available are related to the concavity of the net, its shape and the material used for the net. They are quite expensive but can provide a more secure grasp for some foreign bodies. It is suggested from animal studies and clinical practice that the retrieval net is appropriate for removal of smooth objects (coins, disc batteries or magnets) [35]. In our experience, they are also appropriate for en-bloc removal of food bolus (Fig. 1).

3.4.5. Retrieval snares

Any standard polypectomy snare can be used for foreign body extraction (Fig. 6). These retrieval devices are inexpensive. The main difference between the various snares available is the size of the open loop, which can range from 10 mm × 15 mm to 30 mm × 60 mm for some “jumbo” snares.

3.4.6. Balloons

Balloons can be used for removal of some specific foreign bodies such as gastrotomy tube's bumper, variceal ligator cap, wrench, fractured overtube or bottleneck [36,37].

3.4.7. Protective equipment

Specific equipment must be used in case of sharp or bulky objects, to protect the airways and the oesophageal mucosa. This can be an overtube, whose sheath is slid over the endoscope, before oral introduction. The sheath is pushed down to the endoscope's extremity after the endoscope has been inserted and the foreign body is trapped inside the overtube. Longer overtubes, that cross the gastro-oesophageal junction, should be used when available during removal of sharp or pointed foreign body distal to the oesophagus [7]. Another possibility is the use of a foreign body protector hood, which is placed upside down at the tip of the endoscope, and will unfurl when passing through the lower oesophageal sphincter when pulling out the endoscope and will hence protect the oesophageal mucosa (Fig. 5) [38,39]. Transparent distal caps are smaller but they are widely available from elastic band ligation kits or from endoscopic mucosectomy kits. They can be used either to aspirate impacted food bolus in a steady manner, or to protect the oesophageal wall from sharp or pointed objects (Fig. 7) [40].

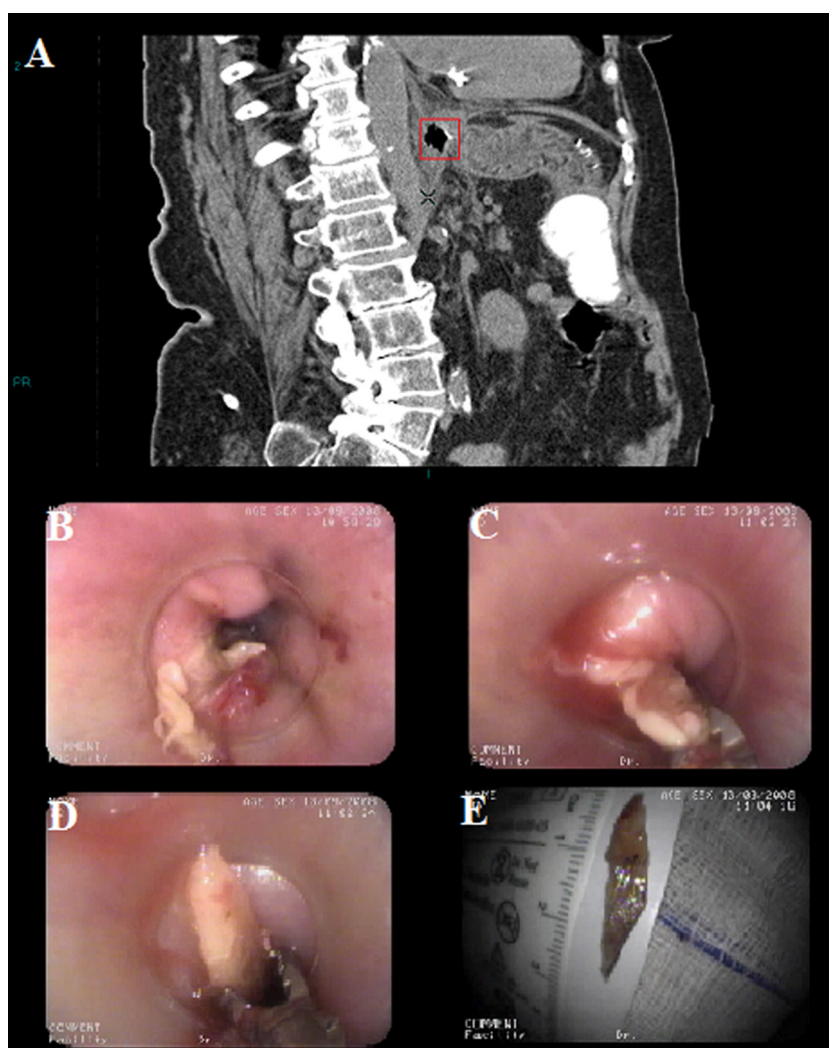


Fig. 7. 95 year-old female patient with past history of strokes and pulmonary embolism, admitted for mediastinitis secondary to accidental ingestion of a sharp bone. Antibiotics, total parenteral nutrition and endoscopic management were proposed. (A) Esophageal perforation is diagnosed on computed-tomography scan; (B–D) successful emergency extraction is performed with a standard gastroscope, a transparent cap and a reusable alligator-tooth foreign body grasper; (E) view of the 3 cm-long sharp bone after removal. No esophageal stenting was performed because a spontaneous drainage of pus into the oesophagus during initial endoscopy. Three-week admission, uneventful outcome.

3.5. Special cases with relation to therapeutic indication, methods and timing

3.5.1. Food bolus impaction

Meat is the most frequent cause of impaction in adults in the Western World (approximately 2/3 of cases) [41], whereas fish-bones are the major cause in Asia (up to 74% of cases) [42]. Risk factors associated with food impaction are use of dentures or pre-existing oesophageal disorders [10]. Whether a fish or meat bone is present in the food bolus impaction must be determined by questioning the patient and sometimes with the help of an X-ray examination.

Urgent treatment is required if the patient cannot swallow saliva because of the risk of inhalation. In any case, removal must be performed within 12–24 h [7,21]. As others, we recommend a time frame of 6 h [43] as the pressure exerted by a foreign body can cause ischaemia, necrosis and lead to perforation or fistula [7,21] if not treated rapidly.

Glucagon (1 mg, intravenously) induces relaxation of the distal oesophagus and may ease the passage of the bolus into the stomach. Nevertheless it showed no significant improvement over a placebo in a multicentre randomised trial [44]. In our opinion, it remains a

safe and acceptable option as long as it does not delay endoscopic removal.

Most acute food impactions occur in the oesophagus, with very limited work space and where underlying diseases (including stenosis) are frequent and sometimes unknown at the time of the procedure (Figs. 1, 2 and 7). Endoscopic suction of stagnant saliva should be repeated throughout the procedure to maintain clear visibility. It is particularly mandatory in the hypopharynx to prevent aspiration. Intubation of the oesophagus must be performed carefully, under strict visual control, to prevent pushing the food bolus (or any associated foreign body such as denture or toothpick) through a diverticulum or to exert uncontrolled pressure on a downstream stenosis (Fig. 3). Once the bolus is reached, the possibility to evaluate the distal oesophageal anatomy is often limited. It is therefore recommended to avoid a blind push of the food bolus towards the stomach. If attempted a safe push technique consists of progressive pressure on the centre of the food bolus, with partial piecemeal resection of the mass if the progression stops [45,46]. Best endoscopic treatments include “en bloc” retrieval (Fig. 1) or piecemeal removal after fragmentation (Fig. 2), using different types of grasping forceps, polypectomy snares, retrieval net or Dormia basket [43]. An overtube is particularly useful in

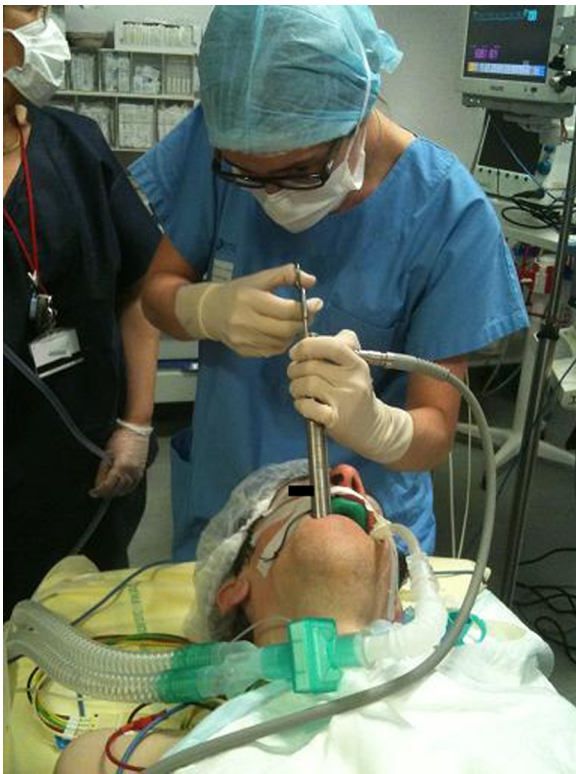

Fig. 8. Rigid oesophagoscopy by a otorhinolaryngologist trainee for extraction of a meat bolus impacted right below the upper esophageal sphincter. Flexible endoscopic removal was attempted but was too tedious. 24 h admission, uneventful outcome.

cases where multiples passages of the endoscope are needed. Some authors have proposed the use of a cap to aspirate larger pieces of the food impaction [40].

Food impaction occurs in 3% of patients with oesophageal or gastroduodenal self-expandable metallic stents (SEMS) [47]. Prevention is based on education of patients to stand upright when eating, to chew thoroughly, to drink sparkling drinks during and after meals, and to avoid mucilages. Patients with short SEMS and underlying malignant disease are at higher risk of food impaction [47]. In the case of stents, push technique should be strictly avoided due to the risk of perforation and stent migration. Stent-in-stent placement should be considered when tumour ingrowth is involved.

3.5.2. Bezoars

Bezoars are foreign material, which can be vegetable fibre (phytobezoar), milk (lactobezoar) or ingested hair (trichobezoar), compacted and retained in the stomach. Risk of bezoar development is correlated to various disorders including gastroparesis and antral resection [48,49], hypertrophic pyloric stenosis, and intestinal pseudo-obstruction [50]. Forceps or snare are used for disaggregation and retrieval of the bezoar. An overtube is useful, because of multiple passages of the endoscope. Removal of larger bezoars may need surgery [48].

3.5.3. Sharp and pointed objects

Any accessible sharp or pointed foreign body should be considered as an emergency and hence extracted without delay [7,21]. The grasping tools for this type of foreign body can be retrieval forceps (Fig. 3), retrieval net and polypectomy snare. Open safety pins can be closed with a polypectomy snare [51]. The risk of injury of the gastric or oesophageal mucosa during the retrieval can be reduced by orientation (sharp tip up) of the object and by the use of protective devices (cap, latex protector hood or overtube) (Figs. 5 and 7) [7,38]. Careful manipulation of the foreign body, to protect the endoscope, should also be considered by the operator.

3.5.4. Long or bulky objects

Recommendations suggest extracting blunt objects longer than 3 cm and 5 cm, in children younger or older than 1 year, respectively [7,9]. In adults, objects larger than 2–2.5 cm or longer than 5–6 cm must be removed before they pass the pylorus, due to an intragastric stagnation in 80% cases and a risk of perforation in 15–35% of the cases if the pylorus is passed [52]. Endoscopy of patients with gastrointestinal foreign body (downstream the oesophagus) can wait for the stomach cavity to be empty in order to reduce the inhalation risk. A retrieval net, a polypectomy snare or a Dormia basket may be used to grasp these objects (Fig. 6). A longer overtube can also be useful. For very long objects, such as spoons or forks, the endoscopic extraction can be hazardous and surgery could eventually be preferential [53]. However, it is sometimes possible to orientate the axis of the foreign body along the axis of the oesophagus using a double operating channel endoscope [10] and using a technique with two snares (Fig. 6) [54].

3.5.5. Coins

Coins are the most frequently ingested foreign body in Western countries [55], particularly in the paediatric population (up to 88% of ingested foreign bodies) [6], and sometimes in adults with psychiatric disorders (Fig. 10) or in prisoners. Children remain asymptomatic in 30–40% of cases even with coin impacted in the oesophagus [56,57]. X-rays easily localise the object in such cases.

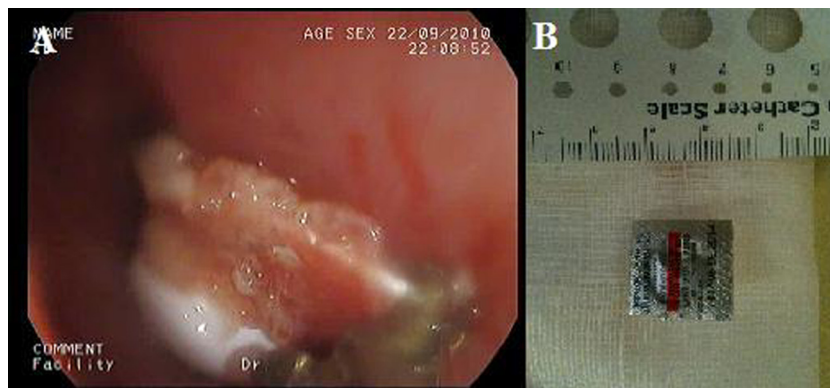


Fig. 9. 85 year-old male patient referred for accidental ingestion of an analgesic tablet with its blister pack. (A) Endoscopic extraction with biopsy forceps; (B) view of the 2 cm large blister after removal. Discharged, uneventful outcome.

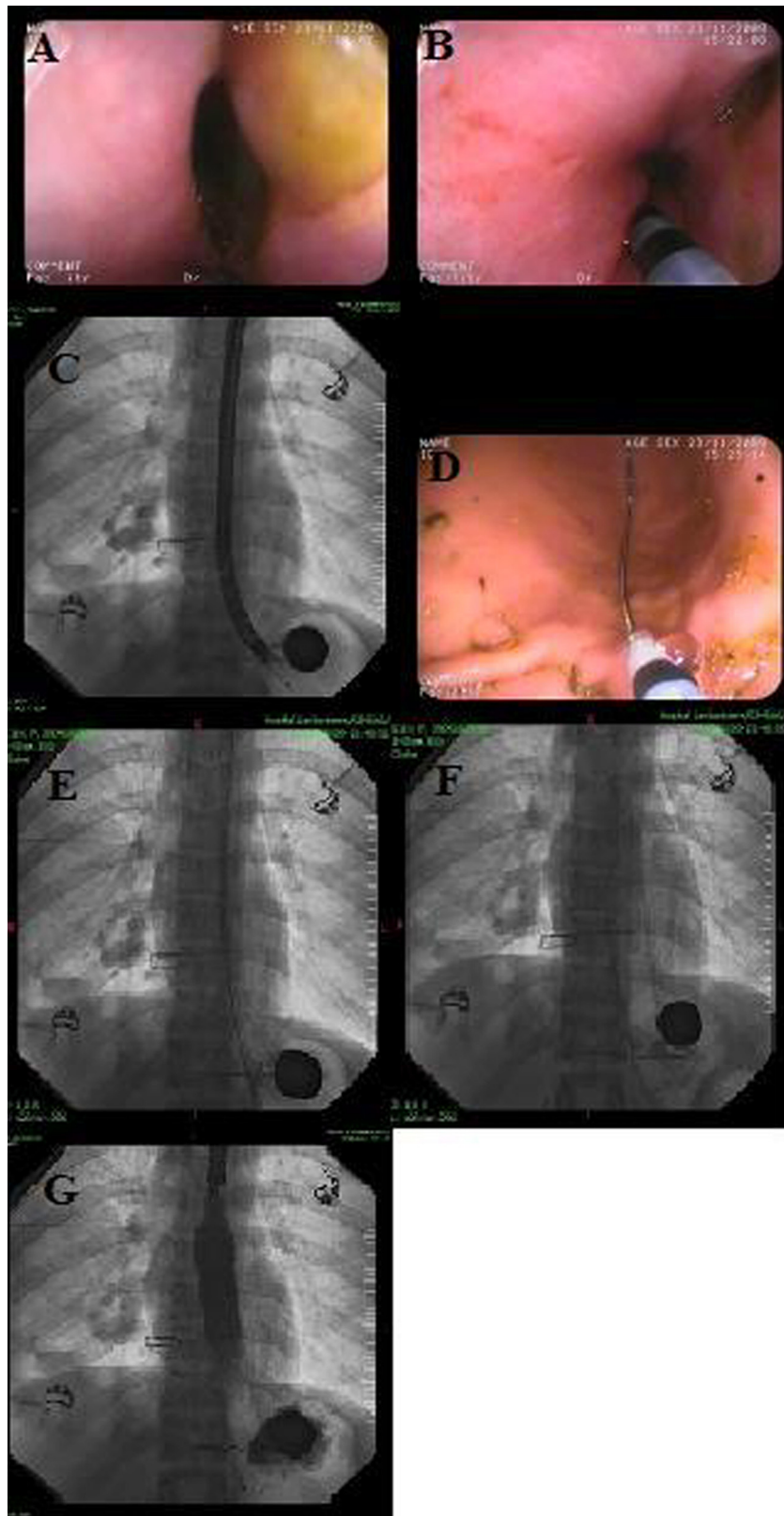


Fig. 10. 16 year-old female referred for endoscopic management of esophageal perforation after endoscopic extraction of razor blades with suicidal intention. (A) Large perforation of the lower oesophagus, (B,C) with contrast leakage in the right pleura. (C) Another foreign body (large coin) is still visible on the X-ray, but extraction was not attempted because of the esophageal perforation; (D,E) insertion of a fully-covered self-expandable metallic stent. Oesophagectomy with mediastinal drainage was performed at day-7 post endoscopy because of a persistence leakage.

Coins should be differentiated from battery on X-rays using the border aspect that is smooth or irregular in coin and show 2 concentric circles in battery. Zinc coins (US pennies) may be corrosive and cause perforation [58,59]. The upper oesophagus is the main site of impaction (73% in children) [6]. Coins should be removed when blocked in the oesophagus, and when larger than 20 mm or with prolonged stasis in the stomach (more than 3 days). Rat-rooth and foreign body grasping forceps are ample enough to grasp coins in most cases.

3.6. Magnets

The attractive force of two or more magnets or of one magnet and a metal object entails a high risk of necrosis with fistula, perforation, occlusion or volvulus [60,61]. Biplane radiographs are important to check if any other metal foreign body is present, which could be hidden behind the magnet in a plain examination. An urgent endoscopy should be performed before the magnet passes the duodenal curve [7,21].

3.7. Batteries

Ingestions of cylindrical battery are rare (0.6% of ingestions) and non severe in most cases. The widespread commercialisation of miniaturised electronic devices and games using more, larger (>20 mm) and higher voltage (3 V) batteries is associated with an increased number of button batteries ingestion since 2004, with more severe and lethal cases [19]. Children are involved in 88% of cases with frequently unwitnessed ingestion (95% of fatal cases and 85% of cases with severe outcomes) [19]. All of the severe complications due to battery ingestion are related to an oesophageal lesion, most of them in children younger than 4 years-old [19]. Button batteries can cause electrical or caustic burns, but also necrosis due to compression of the oesophagus. Toxic effects due to the absorption of the batteries' components (related to the duration of exposure to gastric acidity) can be observed [38,62]. Mercury (but not lithium) intoxication have been reported [63,64], as well as nickel allergic dermatitis [65]. Late complications (tracheoesophageal fistulas, spondylodiscitis, uncontrollable massive bleeding) have been described days and weeks after button battery removal [19,66]. Batteries blocked in the oesophagus must be removed immediately. Batteries that resided in the stomach more than 24 h have also to be endoscopically removed. Eighty-five percent of batteries that have passed in the small intestine will transit through the body within 72 h. A polypectomy retriever net can be used for button disc batteries [35], whereas for regular cylindrical batteries the use of a polypectomy snare is more adequate. A magnetic retriever may be helpful to extract batteries or other metal objects [7].

3.8. Stents

The range of potential complications related to gastrostomy tubes, gastrointestinal, biliary and pancreatic stents is wide and cannot be detailed herein. We will focus on the management of oesophageal partially-covered (PC) and fully-covered (FC) SEMS. PC/FC-SEMS are used as temporary devices in patients with malignant stenosis and in patients with perforation or benign stenosis. PC/FC-SEMS removal is usually easily performed within 6 weeks after placement, by pulling the proximal retrieval lasso or by grasping the proximal metal end of the stent with a polypectomy snare or foreign body retrieval forceps. However, stent removal can be challenging in patients with embedded oesophageal PC/FC-SEMS (due to tissue ingrowth, whether by mucosal hyperplasia or by cancer progression), and in patients with stent migration. In a series of 124 PC-SEMS (68%) and FC-SEMS (32%) stent extraction in 95 patients, van Heel et al. reported on a successful primary removal

in 89% of cases [67]. Unsurprisingly, risk factors for a complicated stent removal were the use of PC-SEMS (rather than FC-SEMS) and longer duration of stent placement [67].

Embedding makes stent removal more traumatic and therefore exposes patient to stricture formation, ulceration, fistula, perforation and haemorrhage. Many techniques for removal of embedded PC/FC-SEMS have been described, without clear recommendation on a preferential technique: pulling the proximal lasso, distal-to-proximal invagination of the stent, use of an overtube, retrieval hoods and retrieval hooks, stent-in-stent placement during 2 weeks (to induce necrosis of tissue ingrowth) [39,68,69]. In case of failure, surgical stent removal should be considered (stent removal through a gastrotomy or radical oesophagectomy in rare cases). In some situations (poor prognosis, uncontrolled malignant disease), leaving the stent in place can be an acceptable option.

Oesophageal SEMS migration occurs in 14–24% of patients [70,71]. Stent migration may lead to an insufficient treatment of the primary disease and is at risk of downstream complications (fistula, perforation and haemorrhage). Removal of displaced oesophageal stent sometimes requires a dilation of an upstream esophageal stricture, before the retrieval of the stent is attempted in the same endoscopic session. The most common method of stent removal involves snaring or grabbing the lasso, pulling on it, thus making the stent end collapse, and finally pulling back the stent through the oeso-cardial junction and the oesophagus without undue traction. As for embedded stents, multiple alternative techniques have been described for extraction of migrated esophageal stents, with no clear preference for one or the other: use of rat-toothed forceps or snare to grab and collapse an end of the stent, balloon insertion in the stent, forceps-in-snare technique [72]. Whatever the technique, a correct collapse of the proximal end of the stent must be obtained, to avoid the metal wire barbs catching on the oesophageal wall.

3.9. Capsules

Capsule endoscopy is associated with retention rates of around 1.4% [73], mostly in patients with unexpected stricture or diverticulum [73]. Among 31 cases of capsule retention (1.3%) in a series of 2900 capsule examinations, surgery was performed in 27 patients (urgent surgery in 7 patients) and double-balloon enteroscopy removal in 1 patient. The capsule was left in situ in 3 patients [74].

Capsule retention in the oesophagus (in a diverticulum for example [75]) or in the stomach is usually not problematic. In patients with capsule retention in Crohn's disease stricture, corticosteroid treatment may be attempted as a first-line therapy. In cases where endoscopic capsule removal from the small bowel is indicated, two different challenges should be anticipated [76]. Firstly, accessing the capsule is sometimes difficult. When capsule retention is proximal to the mid-jejunum, upper endoscopy or push enteroscopy can be attempted. In other cases, upper or lower colonoscopy, double-balloon enteroscopy or spiral-overtube enteroscopy should be considered, according to the site of capsule retention and to the presence of downstream strictures. Secondly, ancillary instruments should be long and thin enough to be introduced through the operating channel of the chosen enteroscope. Polypectomy snares seem to be appropriate in most cases to pull and place the capsule back in the stomach. A polypectomy retriever net may then be used with a gastroscope to grab the capsule from the stomach and pass the upper oesophagus with the capsule [76]. Surgery can be considered in case of obstructive symptoms (before or after unsuccessful endoscopic approaches).

3.10. Narcotic packets

Body packing consists of swallowing or inserting into the rectum illicit drugs packed within balloons or latex condoms. Endoscopic

removal is not recommended because rupture and leakage of the contents can be fatal [21,77]. High risk of narcotic intoxication is present in case of symptomatic patients, of digestive retention longer than 48 h after ingestion, of poor resistance packages or broken containers as demonstrated on X-rays [78]. Radiographic monitoring is recommended and surgery is required in case of suspected leakage of packet, intestinal obstruction or stagnation of the packet in the bowel [21].

4. Results of endoscopic management

In most series, the success rate of endoscopic removal of food bolus impaction and foreign body removal from the upper digestive tract is around 95% [2,10]. It has been showed in animal models that experienced endoscopists achieve endoscopic extraction of foreign body with higher success rates and faster than fellows-in-training [35].

Even in cases where timing is optimal (urgent or less than 6 h), in 30% no foreign body can be found in the upper digestive tract [2]. In cases in which dangerous foreign body (sharp, pointed or long objects, batteries or magnets) have passed the Treitz' angle, enteroscopy and surgery should be considered for removal. In cases with a lower risk of perforation, daily stool observation and abdominal X-ray every 3 days are necessary to assess the progress through the gastro-intestinal tract [21]. Patients should be aware of the clinical signs of intestinal perforation (sudden pain, fever, ileus).

In case of failure to remove a foreign body, several options should be considered. For upper oesophageal foreign body, rigid oesophagoscopy can be attempted (Fig. 8). Referral to a more experienced endoscopist and/or to a centre with a larger armamentarium may help (2% in adult series) [2]. Surgery is sometimes required (1% in the same series) [2].

Rates of complication after foreign body ingestion varies from 0% to 38% of cases, according to what is considered a complication (such as mucosal erosions in some series) [2,33,42,79–81]. Severe complications (including perforations, obstructions, local or regional infections [62], massive bleeding [11], fistula and foreign body migrations through the digestive wall [82]) are rare (1–5%) [2,33,42,79–81]. Oesophageal perforation is the most frequent (2%) and most feared complication (Fig. 7) [18]. Mortality rate is low, with a single lethal case in a series of 2206 children [83], and with 5 severe but non-lethal outcomes in 127,000 foreign body ingestions in adults [1].

According to a Chinese monocentric retrospective series including 225 patients with a complication rate of 9.7%, risk factors for complications (including ulcers, lacerations and erosions) were the following: time interval between ingestion and admission over 24 h, positive radiographic findings and age over 50 years [42]. In the series of 316 oesophageal foreign bodies by Sung et al. analysing similar complications, identified independent risk factors were: duration of impaction over 24 h, bone-type foreign body and size over 30 mm [81]. In a retrospective study of 1338 patients from Hong Kong with complication rate of 2.8%, independent risk factors of complications were presentation over 2 days, positive cervical radiographic findings and impaction above the mid-oesophagus [80]. Although most large series assessing risk factors for complications are from Asia (with different foreign body types relative to the Western World) and retrospective, it is likely that the key messages are the same in other situations:

- (i) Most severe complications (including perforation) occur before any treatment and severe complications related to endoscopic procedures are uncommon. In a prospective study including 105 cases, the overall rate of complications was 38% and the rate of complications occurring during endoscopic removal was 9%, of which 1% was perforations [79].
- (ii) It is very important to quickly recognise if a significant complication has occurred after foreign body extraction because the earlier the treatment is applied, the better the outcome. The possibility of a delayed perforation due to tissue necrosis must be kept in mind. For all these reasons, 24-h admission to hospital must be considered if the retrieval was difficult, with clinical monitoring of perforation symptoms.
- (iii) When a perforation does occur, multiple treatment options are available. Endoscopic treatment can be a good option, if the perforation is diagnosed early. Immediate endoscopic clipping is appropriate when the perforation is small, before advanced contamination of the mediastinum sets in. FC-SEMS placement, covering the perforation to prevent continuing septic contamination and to aid re-epithelisation of the mucosal gap and to allow early feeding, is another acceptable option (Fig. 10) [84]. Total parenteral nutrition, broad-spectrum antibiotics (targeting aerobic and anaerobic germs, for a period 14–21 days) and proton pump inhibitors are the basis of the medical treatment. When endoscopic treatment is impossible, surgical treatment is required.

5. Follow-up

Underlying gastrointestinal diseases are frequent in patients with ingested foreign bodies, with special mention to eosinophilic esophagitis [14]. This calls for an elective endoscopy with biopsies. In situations without any severe damage at the site of impaction (either due to the foreign body itself or to the removal procedure), immediate biopsies (Fig. 3) and dilation can be proposed to document or treat specific lesions. In all other cases, diagnostic and therapeutic procedures should be scheduled (Fig. 2). Management of non-gastrointestinal conditions (dentures, psychiatric disorders) should not be overlooked.

Prasad et al. assessed risk factors of recurrence of food bolus impaction by retrospectively comparing 52 patients with recurrence of food bolus impaction to 124 controls without recurrence over an 11-year period. Presence of a diaphragmatic hernia, retrieval by piecemeal extraction and acquisition of oesophageal biopsies were associated with a significantly increased risk of recurrent food impaction, whereas physician follow-up after the initial episode significantly decreased this risk [85].

6. Conclusion

Ingestion of foreign body and food bolus impaction is frequent. Most of the foreign bodies will naturally pass through the gastrointestinal tract, however some cases will need early medical intervention. The role of the gastroenterologist is to recognise these situations and to plan endoscopic removal in a timely manner with the most adapted and adequate equipment. Finally, when blockages in the oesophagus occur, risk factors and underlying oesophageal pathology must be investigated and treated if necessary.

Acknowledgements

The authors would like to thank Cedric Mendes-Unsworth for the English proofreading of the manuscript, and all the endoscopists participating to the Emergency Endoscopy Unit of the Assistance Publique–Hôpitaux de Paris for their critical revision of this review: Aurelien Amiot, Cyriaque Bon, Marine Camus, Ulriikka Chaput, Olivier Corcos, Romain Coriat, Pascal Crenn, Gael Goujon, Pascal Hammel, Sarah Leblanc, Pierre Nahon, Violaine Ozenne, Benjamin Pariente, Elia Samaha, Milad Taouk.

- (i) Most severe complications (including perforation) occur before any treatment and severe complications related to endoscopic procedures are uncommon. In a prospective study including 105 cases, the overall rate of complications was 38%

References

- [1] Bronstein AC, Spyker DA, Cantilena Jr LR, et al. 2007 Annual Report of the American Association of Poison Control Centers' National Poison Data System (NPDS): 25th Annual Report. *Clinical Toxicology* (Philadelphia, PA) 2008;46: 927–1057.
- [2] Mosca S, Manes G, Martino R, et al. Endoscopic management of foreign bodies in the upper gastrointestinal tract: report on a series of 414 adult patients. *Endoscopy* 2001;33:692–6.
- [3] Witcombe B, Meyer D. Sword swallowing and its side effects. *BMJ (Clinical Research Edition)* 2006;333:1285–7.
- [4] Koornstra JJ, Weersma RK. Management of rectal foreign bodies: description of a new technique and clinical practice guidelines. *World Journal of Gastroenterology* 2008;14:4403–6.
- [5] Chinski A, Foltran F, Gregori D, et al. Foreign bodies in the oesophagus: the experience of the Buenos Aires paediatric ORL clinic. *International Journal of Pediatrics* 2010;2010:490691.
- [6] Little DC, Shah SR, St Peter SD, et al. Esophageal foreign bodies in the pediatric population: our first 500 cases. *Journal of Pediatric Surgery* 2006;41:914–8.
- [7] Michaud L, Bellaiche M, Olives JP. Ingestion of foreign bodies in children. Recommendations of the French-Speaking Group of Pediatric Hepatology, Gastroenterology and Nutrition. *Archives de Pédologie* 2009;16:54–61.
- [8] Diniz LO, Towbin AJ. Causes of esophageal food bolus impaction in the pediatric population. *Digestive Diseases and Sciences* 2012;57:690–3.
- [9] Eisen GM, Baron TH, Dominitz JA, et al. Guideline for the management of ingested foreign bodies. *Gastrointestinal Endoscopy* 2002;55:802–6.
- [10] Li ZS, Sun ZX, Zou DW, et al. Endoscopic management of foreign bodies in the upper-GI tract: experience with 1088 cases in China. *Gastrointestinal Endoscopy* 2006;64:485–92.
- [11] Zhang S, Cui Y, Gong X, et al. Endoscopic management of foreign bodies in the upper gastrointestinal tract in South China: a retrospective study of 561 cases. *Digestive Diseases and Sciences* 2010;55:1305–12.
- [12] Roth M, Cohen G. A quarter causing intermittent gastric outlet obstruction. *Gastrointestinal Endoscopy* 2012;75:189, discussion 90.
- [13] Chlak S, Foucar H. Report of a case in which more than 2500 foreign bodies were found. *Archives of Surgery* 1928;16:494–500.
- [14] Sperry SL, Crockett SD, Miller CB, et al. Esophageal foreign-body impactions: epidemiology, time trends, and the impact of the increasing prevalence of eosinophilic esophagitis. *Gastrointestinal Endoscopy* 2011;74:985–91.
- [15] Chen MK, Beierle EA. Gastrointestinal foreign bodies. *Pediatric Annals* 2001;30:736–42.
- [16] O'Connor TE, Cooney T. Oesophageal foreign body and a double aortic arch: rare dual pathology. *The Journal of Laryngology and Otology* 2009;123: 1404–6.
- [17] Soerdjbalie-Maikoe V, van Rijn RR. A case of fatal coin battery ingestion in a 2-year-old child. *Forensic Science International* 2010;198:e19–22.
- [18] Tokar B, Cevik AA, Ilhan H. Ingested gastrointestinal foreign bodies: predisposing factors for complications in children having surgical or endoscopic removal. *Pediatric Surgery International* 2007;23:135–9.
- [19] Litovitz T, Whitaker N, Clark L, et al. Emerging battery-ingestion hazard: clinical implications. *Pediatrics* 2010;125:1168–77.
- [20] Zhang X, Liu J, Li J, et al. Diagnosis and treatment of 32 cases with aorto-esophageal fistula due to esophageal foreign body. *The Laryngoscope* 2011;121:267–72.
- [21] Ikenberry SO, Jue TL, Anderson MA, et al. Management of ingested foreign bodies and food impactions. *Gastrointestinal Endoscopy* 2011;73:1085–91.
- [22] Spitz L. Management of ingested foreign bodies in childhood. *British Medical Journal* 1971;4:469–72.
- [23] Suita S, Ohgami H, Nagasaki A, et al. Management of pediatric patients who have swallowed foreign objects. *The American Surgeon* 1989;55:585–90.
- [24] MacManus J. Perforations in the intestine by ingested foreign bodies. *American Journal of Surgery* 1941;53:393.
- [25] Karaman A, Karaman I, Erdogan D, et al. Perforation of Meckel's diverticulum by a button battery: report of a case. *Surgery Today* 2007;37:1115–6.
- [26] Willis GA, Ho WC. Perforation of Meckel's diverticulum by an alkaline hearing aid battery. *Canadian Medical Association Journal* 1982;126:497–8.
- [27] Yagci G, Cetiner S, Tufan T. Perforation of Meckel's diverticulum by a chicken bone, a rare complication: report of a case. *Surgery Today* 2004;34:606–8.
- [28] Uyemura MC. Foreign body ingestion in children. *American Family Physician* 2005;72:287–91.
- [29] Arana A, Hauser B, Hachimi-Idrissi S, et al. Management of ingested foreign bodies in childhood and review of the literature. *European Journal of Pediatrics* 2001;160:468–72.
- [30] Connolly AA, Birchall M, Walsh-Waring GP, et al. Ingested foreign bodies: patient-guided localization is a useful clinical tool. *Clinical Otolaryngology and Allied Sciences* 1992;17:520–4.
- [31] Jovanovic I, Vormbrock K, Zimmermann L, et al. Therapeutic double-balloon enteroscopy: a binaural, three-center experience. *Digestive Diseases (Basel, Switzerland)* 2011;29(Suppl. 1):27–31.
- [32] Kim JK, Kim SS, Kim JI, et al. Management of foreign bodies in the gastrointestinal tract: an analysis of 104 cases in children. *Endoscopy* 1999;31:302–4.
- [33] Berggreen PJ, Harrison E, Sanowski RA, et al. Techniques and complications of esophageal foreign body extraction in children and adults. *Gastrointestinal Endoscopy* 1993;39:626–30.
- [34] Diehl DL, Adler DG, Conway JD, et al. Endoscopic retrieval devices. *Gastrointestinal Endoscopy* 2009;69:997–1003.
- [35] Faigel DO, Stotland BR, Kochman ML, et al. Device choice and experience level in endoscopic foreign object retrieval: an in vivo study. *Gastrointestinal Endoscopy* 1997;45:490–2.
- [36] Matsushita M, Shimatani M, Uchida K, et al. Endoscopic removal of hollow colorectal foreign bodies with the use of a balloon catheter. *Gastrointestinal Endoscopy* 2009;69:604–5, author reply 5.
- [37] Munoz JC, Habashi S, Corregidor AM, et al. Extraction of hollow gastric foreign bodies by flexible upper endoscopy assisted by a through-the-scope balloon catheter for anchoring. *Gastrointestinal Endoscopy* 2008;67:519–21.
- [38] Bertoni G, Sassatelli R, Conigliaro R, et al. A simple latex protector hood for safe endoscopic removal of sharp-pointed gastroesophageal foreign bodies. *Gastrointestinal Endoscopy* 1996;44:458–61.
- [39] Bertoni G, Pacchione D, Sassatelli R, et al. A new protector device for safe endoscopic removal of sharp gastroesophageal foreign bodies in infants. *Journal of Pediatric Gastroenterology and Nutrition* 1993;16:393–6.
- [40] Pezzi JS, Shiau YF. A method for removing meat impactions from the oesophagus. *Gastrointestinal Endoscopy* 1994;40:634–6.
- [41] Kirchner G, Zuber-Jerger I, Endlicher E, et al. Causes of bolus impaction in the oesophagus. *Surgical Endoscopy* 2011;25:3170–4.
- [42] Hung CW, Hung SC, Lee CJ, et al. Risk factors for complications after a foreign body is retained in the oesophagus. *The Journal of Emergency Medicine* 2012;43:423–7.
- [43] Mosca S. Management and endoscopic techniques in cases of ingestion of foreign bodies. *Endoscopy* 2000;32:272–3.
- [44] Tibbling L, Björkholm A, Jansson E, et al. Effect of spasmolytic drugs on esophageal foreign bodies. *Dysphagia* 1995;10:126–7.
- [45] Longstreth GF, Longstreth KJ, Yao JF. Esophageal food impaction: epidemiology and therapy. A retrospective, observational study. *Gastrointestinal Endoscopy* 2001;53:193–8.
- [46] Vicari JJ, Johanson JF, Frakes JT. Outcomes of acute esophageal food impaction: success of the push technique. *Gastrointestinal Endoscopy* 2001;53:178–81.
- [47] Song M, Song HY, Kim JH, et al. Food impaction after expandable metal stent placement: experience in 1360 patients with esophageal and upper gastrointestinal tract obstruction. *Journal of Vascular and Interventional Radiology* 2011;22:1293–9.
- [48] Erzurumlu K, Malazgirt Z, Bektas A, et al. Gastrointestinal bezoars: a retrospective analysis of 34 cases. *World Journal of Gastroenterology* 2005;11:1813–7.
- [49] Robles R, Parrilla P, Escamilla C, et al. Gastrointestinal bezoars. *The British Journal of Surgery* 1994;81:1000–1.
- [50] Wyatt JP, Haddock G, Aitken RJ. Gastric phytobezoar: unusual association and resolution. *Postgraduate Medical Journal* 1993;69:659–60.
- [51] Kalayci A, Tander B, Kocak S, Rizalar R, Bernay F. Removal of open safety pins in infants by flexible endoscopy is effective and safe. *Journal of Laparoendoscopic and Advanced Surgical Techniques* 2007;17:242–5.
- [52] Palta R, Sahota A, Bemarki A, Salama P, Simpson N, Laine L. Foreign-body ingestion: characteristics and outcomes in a lower socioeconomic population with predominantly intentional ingestion. *Gastrointestinal Endoscopy* 2009;69:426–33.
- [53] Velitchkov KN, Grigorov GI, Losanoff JE, Kjossev KT. Ingested foreign bodies of the gastrointestinal tract: retrospective analysis of 542 cases. *World Journal of Surgery* 1996;20:1001–5.
- [54] Yong PT, Teh CH, Look M, et al. Removal of a dinner fork from the stomach by double-snare endoscopic extraction. *Hong Kong Medical Journal=Xianggang yi xue za zhi/Hong Kong Academy of Medicine* 2000;6:319–21.
- [55] Webb WA. Management of foreign bodies of the upper gastrointestinal tract: update. *Gastrointestinal Endoscopy* 1995;41:39–51.
- [56] Hodge 3rd D, Tecklenburg F, Fleisher G. Coin ingestion: does every child need a radiograph? *Annals of Emergency Medicine* 1985;14:443–6.
- [57] Schunk JE, Corneli H, Bolte R. Pediatric coin ingestions. A prospective study of coin location and symptoms. *American Journal of Diseases of Children* (1960) 1989;143:546–8.
- [58] Hesham AKH. Foreign body ingestion: children like to put objects in their mouth. *World Journal of Pediatrics* 2010;6:301–10.
- [59] Bennett DR, Baird CJ, Chan KM, et al. Zinc toxicity following massive coin ingestion. *The American Journal of Forensic Medicine and Pathology* 1997;18:148–53.
- [60] Gastrointestinal injuries from magnet ingestion in children—United States, 2003–2006. *MMWR: Morbidity and Mortality Weekly Report* 2006;55:1296–300.
- [61] Sahin C, Alver D, Gulcin N, Kurt G, Celayir AC. A rare cause of intestinal perforation: ingestion of magnet. *World Journal of Pediatrics* 2010;6:369–71.
- [62] Lin M, Mohammed H, Lavien G, Brazio P, Lumpkins K, Timmons T. Sacral osteomyelitis: an unusual complication from foreign body ingestion. *The American Surgeon* 2012;78:497–9.
- [63] Kulig K, Rumack CM, Rumack BH, et al. Disk battery ingestion. Elevated urine mercury levels and enema removal of battery fragments. *JAMA* 1983;249:2502–4.
- [64] Mant TG, Lewis JL, Mattoo TK, et al. Mercury poisoning after disc-battery ingestion. *Human Toxicology* 1987;6:179–81.
- [65] Litovitz T, Schmitz BF. Ingestion of cylindrical and button batteries: an analysis of 2382 cases. *Pediatrics* 1992;89:747–57.
- [66] Sudhakar PJ, Dossary JA, Malik N. Spondylodiscitis complicated by the ingestion of a button battery: a case report. *Korean Journal of Radiology* 2008;9:555–8.
- [67] van Heel NC, Haringsma J, Wijnhoven BP, et al. Endoscopic removal of self-expandable metal stents from the oesophagus (with video). *Gastrointestinal Endoscopy* 2011;74:44–50.

- [68] Yan SL, Chen CH, Yeh YH, et al. Endoscopic removal of an embedded partially covered esophageal self-expandable metallic stent by overtube technique. *Endoscopy* 2011;43(Suppl. 2). UCTN:E400-1.
- [69] Yoon CJ, Shin JH, Song HY, et al. Removal of retrievable esophageal and gastrointestinal stents: experience in 113 patients. *AJR: American Journal of Roentgenology* 2004;183:1437–44.
- [70] Repici A, Conio M, De Angelis C, et al. Temporary placement of an expandable polyester silicone-covered stent for treatment of refractory benign esophageal strictures. *Gastrointestinal Endoscopy* 2004;60:513–9.
- [71] Siersema PD. Stenting for benign esophageal strictures. *Endoscopy* 2009;41:363–73.
- [72] Farkas PS, Farkas JD, Koenigs KP. An easier method to remove migrated esophageal Z-stents. *Gastrointestinal Endoscopy* 1999;50:277–9.
- [73] Liao Z, Gao R, Xu C, et al. Indications and detection, completion, and retention rates of small-bowel capsule endoscopy: a systematic review. *Gastrointestinal Endoscopy* 2010;71:280–6.
- [74] Hoog CM, Bark LA, Arkani J, et al. Capsule retentions and incomplete capsule endoscopy examinations: an analysis of 2300 examinations. *Gastroenterology Research and Practice* 2012;2012:518718.
- [75] Ziachehabi A, Maieron A, Hoheisel U, et al. Capsule retention in a Zenker's diverticulum. *Endoscopy* 2011;43(Suppl. 2). UCTN:E387.
- [76] Roorda AK, Kupec JT, Ostrinsky Y, et al. Endoscopic approach to capsule endoscope retention. *Expert Review of Gastroenterology and Hepatology* 2010;4:713–21.
- [77] Boehnert MT, Lewander WJ, Gaudreault P, et al. Advances in clinical toxicology. *Pediatric Clinics of North America* 1985;32:193–211.
- [78] Caruana DS, Weinbach B, Goerg D, et al. Cocaine-packet ingestion. Diagnosis, management, and natural history. *Annals of Internal Medicine* 1984;100:73–4.
- [79] Chaves DM, Ishioka S, Felix VN, et al. Removal of a foreign body from the upper gastrointestinal tract with a flexible endoscope: a prospective study. *Endoscopy* 2004;36:887–92.
- [80] Lai AT, Chow TL, Lee DT, et al. Risk factors predicting the development of complications after foreign body ingestion. *The British Journal of Surgery* 2003;90:1531–5.
- [81] Sung SH, Jeon SW, Son HS, et al. Factors predictive of risk for complications in patients with oesophageal foreign bodies. *Digestive and Liver Disease* 2011;43:632–5.
- [82] Ozkan Z, Kement M, Kargi AB, et al. An interesting journey of an ingested needle: a case report and review of the literature on extra-abdominal migration of ingested foreign bodies. *Journal of Cardiothoracic Surgery* 2011;6:77.
- [83] Cheng W, Tam PK. Foreign-body ingestion in children: experience with 1265 cases. *Journal of Pediatric Surgery* 1999;34:1472–6.
- [84] Chirica M, Champault A, Dray X, et al. Esophageal perforations. *Journal of Visceral Surgery* 2010;147:e117–28.
- [85] Prasad GA, Reddy JG, Boyd-Enders FT, et al. Predictors of recurrent esophageal food impaction: a case-control study. *Journal of Clinical Gastroenterology* 2008;42:771–5.